

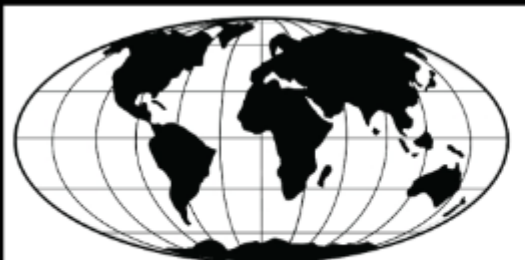Case 8

Dr. Charles Artiles, DVM

Resident in Diagnostic Imaging

Dr. Chee Kin Lim, DVM, BVSc(Hons), MMedVet (Diag Im), FMCVS (Vet Imaging), Dipl ECVDI

Clinical Associate Professor, Diagnostic Imaging



IVRA | INTERNATIONAL VETERINARY
RADIOLOGY ASSOCIATION



College of Veterinary Medicine

Signalment and history

- 3 yo Bay Thoroughbred gelding
- Presented for acute lameness of the right front limb for four days duration since the race

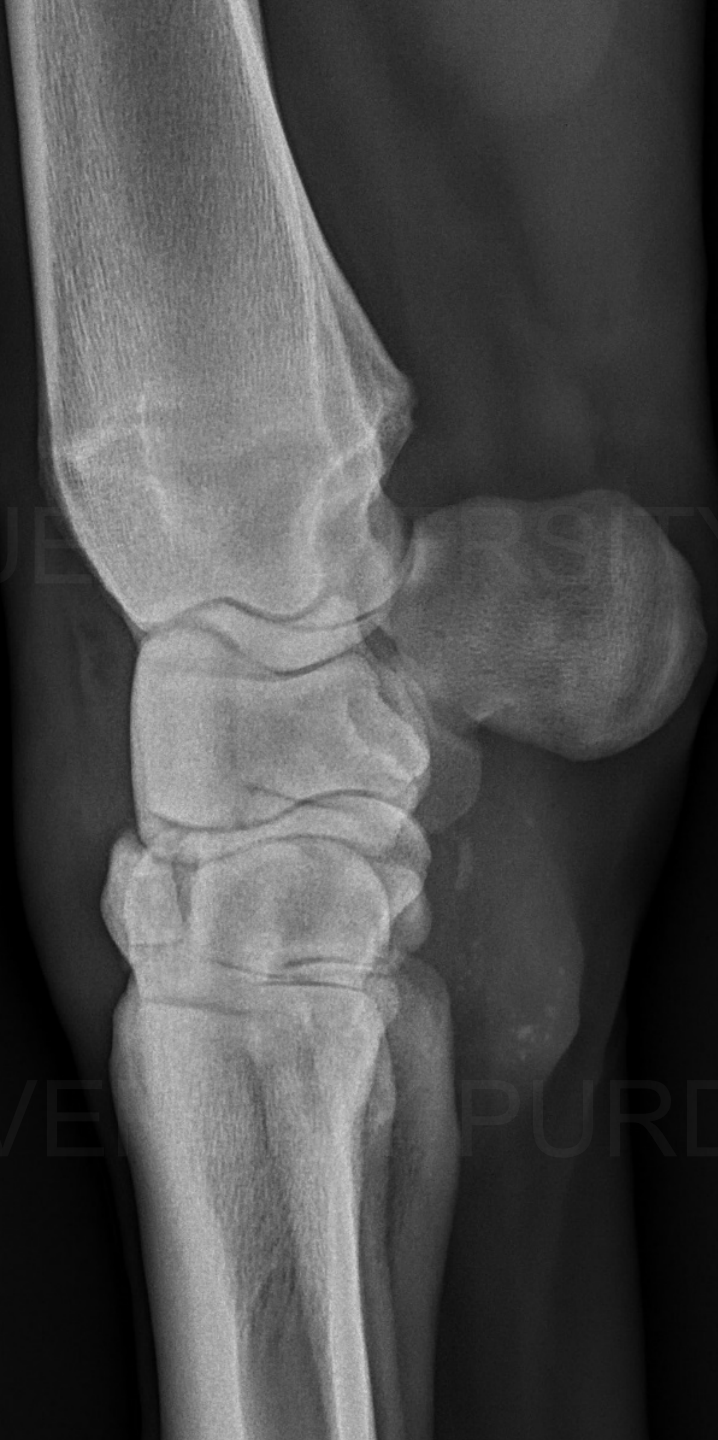Physical exam findings

- Lameness grade 4/5 on right front limb
- Heat and mild swelling present on the dorsal aspect of the right carpus
- Rest of physical exam was unremarkable

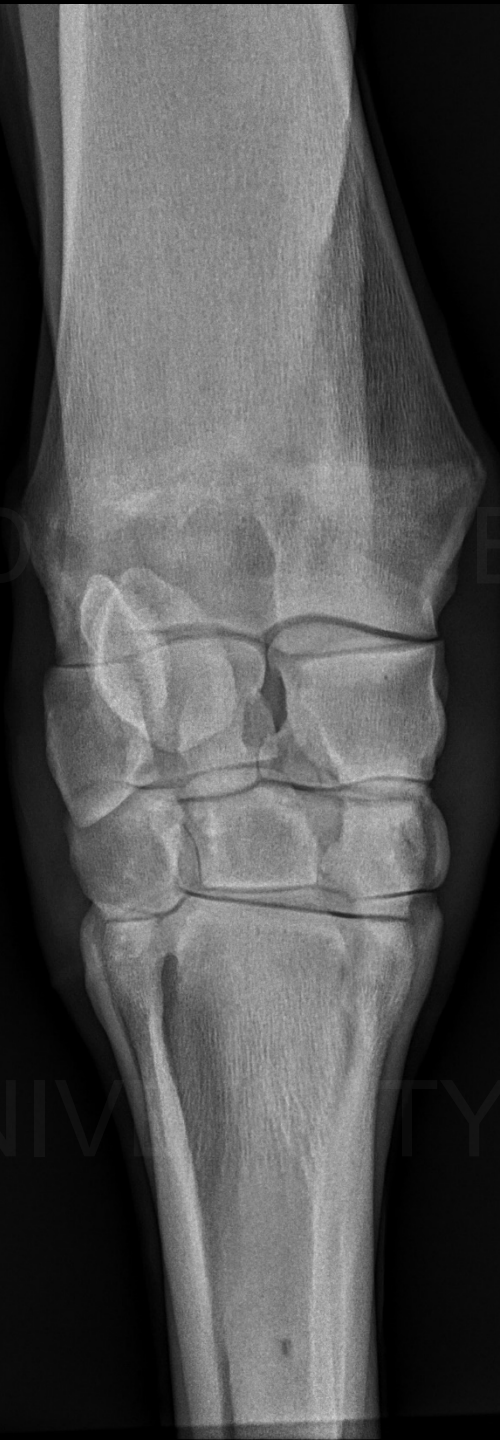Radiographs of the right carpus are available

- 1) Describe your radiological findings
- 2) List your diagnosis/differential diagnoses

LM
RFRONT

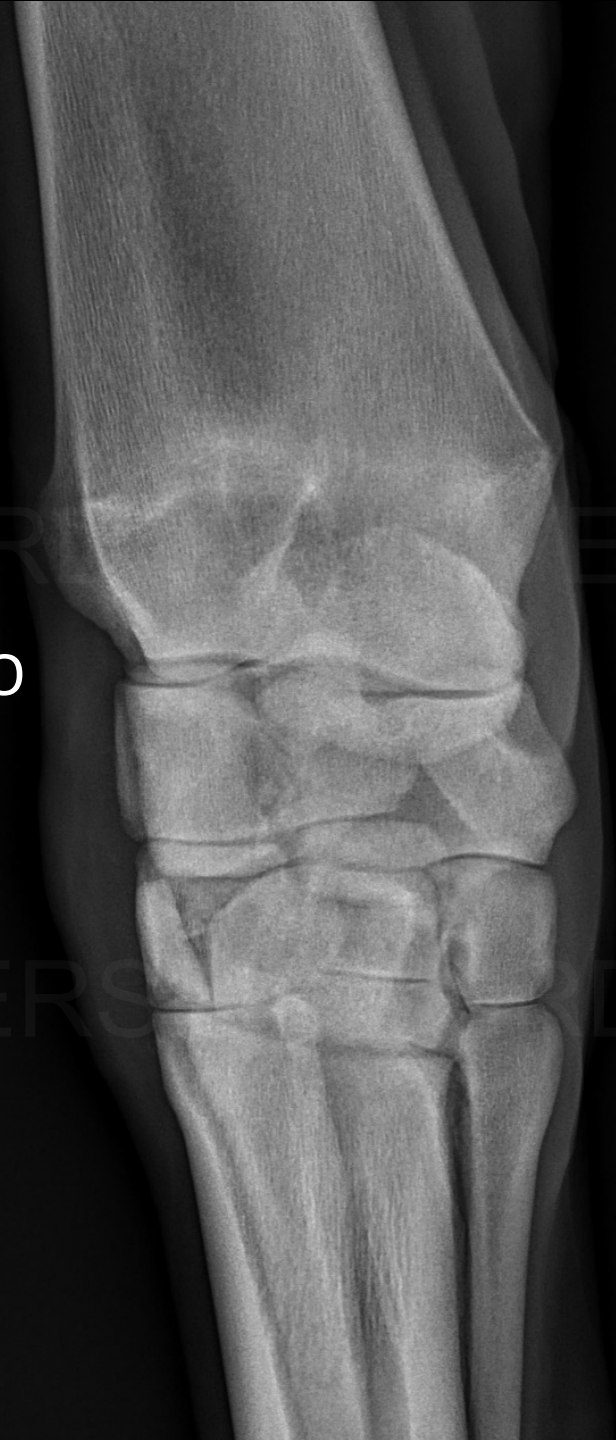

DP
RFRONT



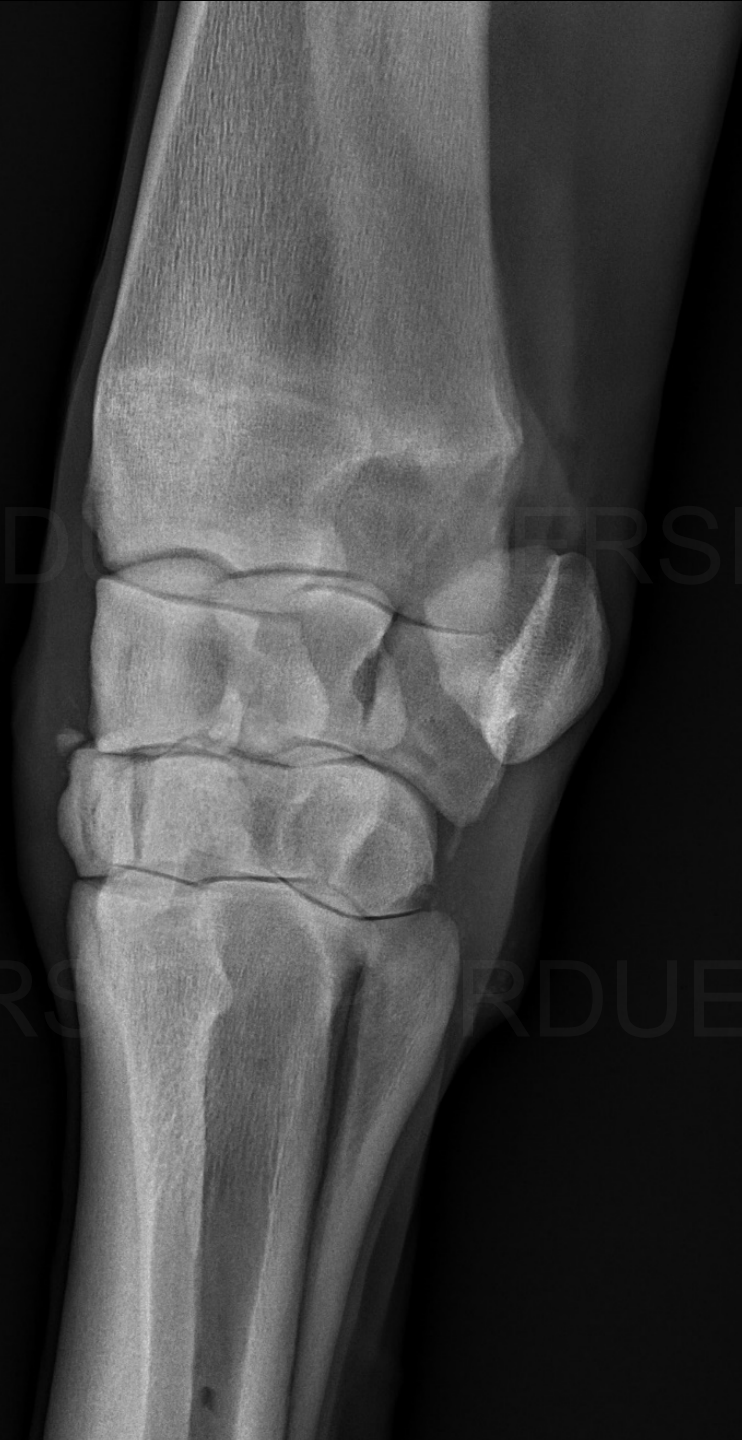DMPLO

RFRONT




DMPLO


RFRONT



What other views might be beneficial??

A lateral radiograph of a flexed elbow joint. The humerus is at the top, and the radius and ulna are visible below it. The joint space is clearly defined.

LM flexed
RFRONT

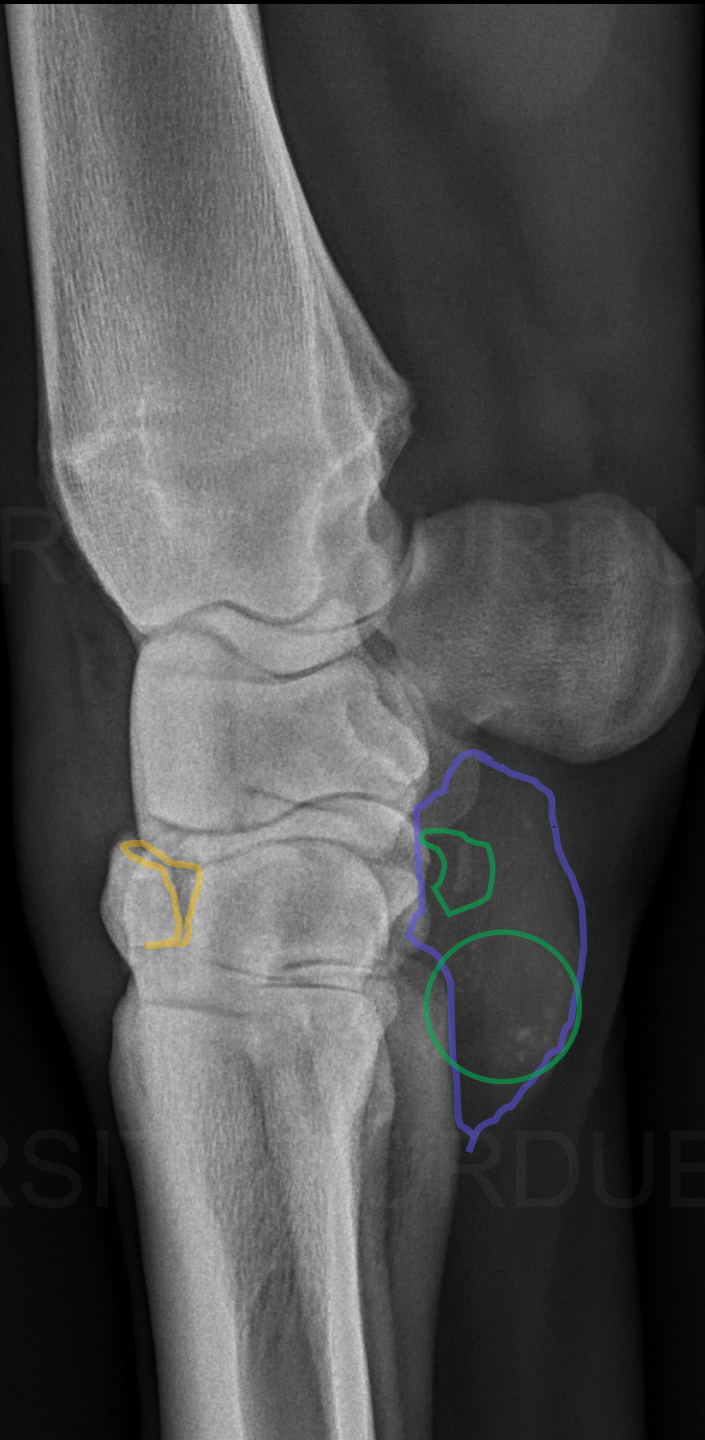
A D35° PrDDiO ('skyline view') radiograph of the elbow joint. The image shows the distal humerus and the proximal radius and ulna in a specific projection, highlighting the joint's structure.

D35° PrDDiO
('skyline view')
RFRONT

Radiological findings

Well defined, wedge to linear shaped decreased mineral opacity in the cranial aspect of the 3rd carpal bone

LM
RFRONT



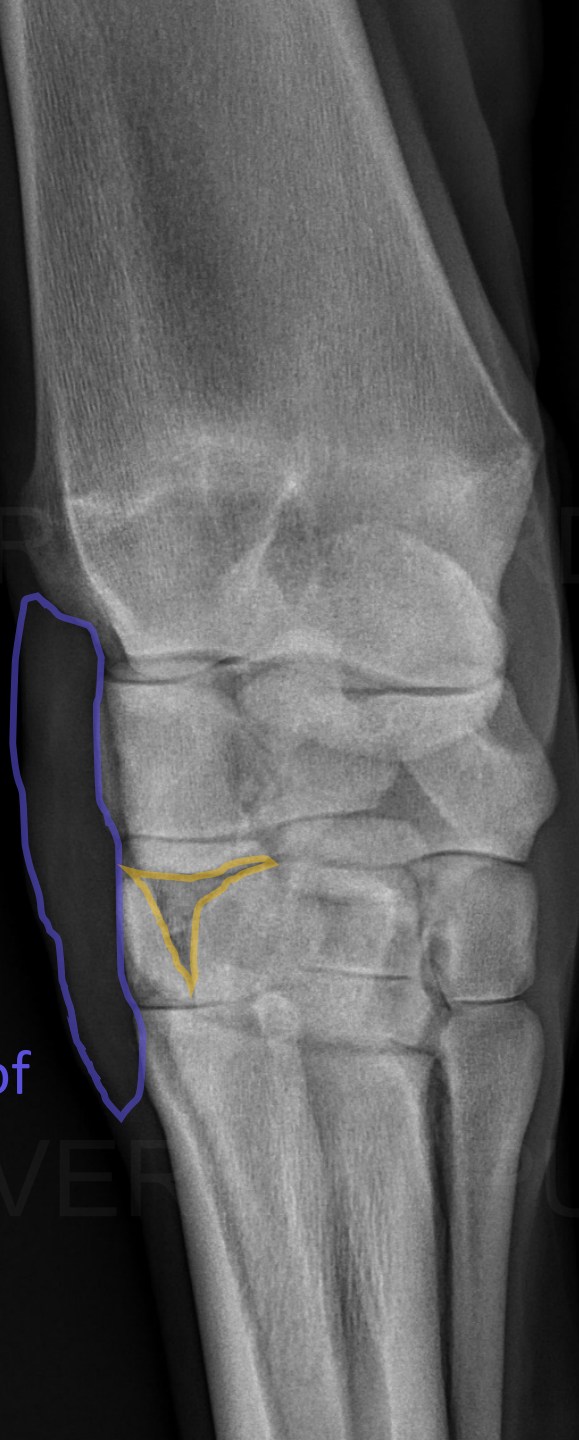
Increased soft tissue swelling, palmar to the intercarpal and carpometacarpal joints

Multiple small rounded and one short linear mineral fragments

DMPLO
RFRONT

Increased soft tissue
swelling at the
dorsolateral aspect of
the carpus

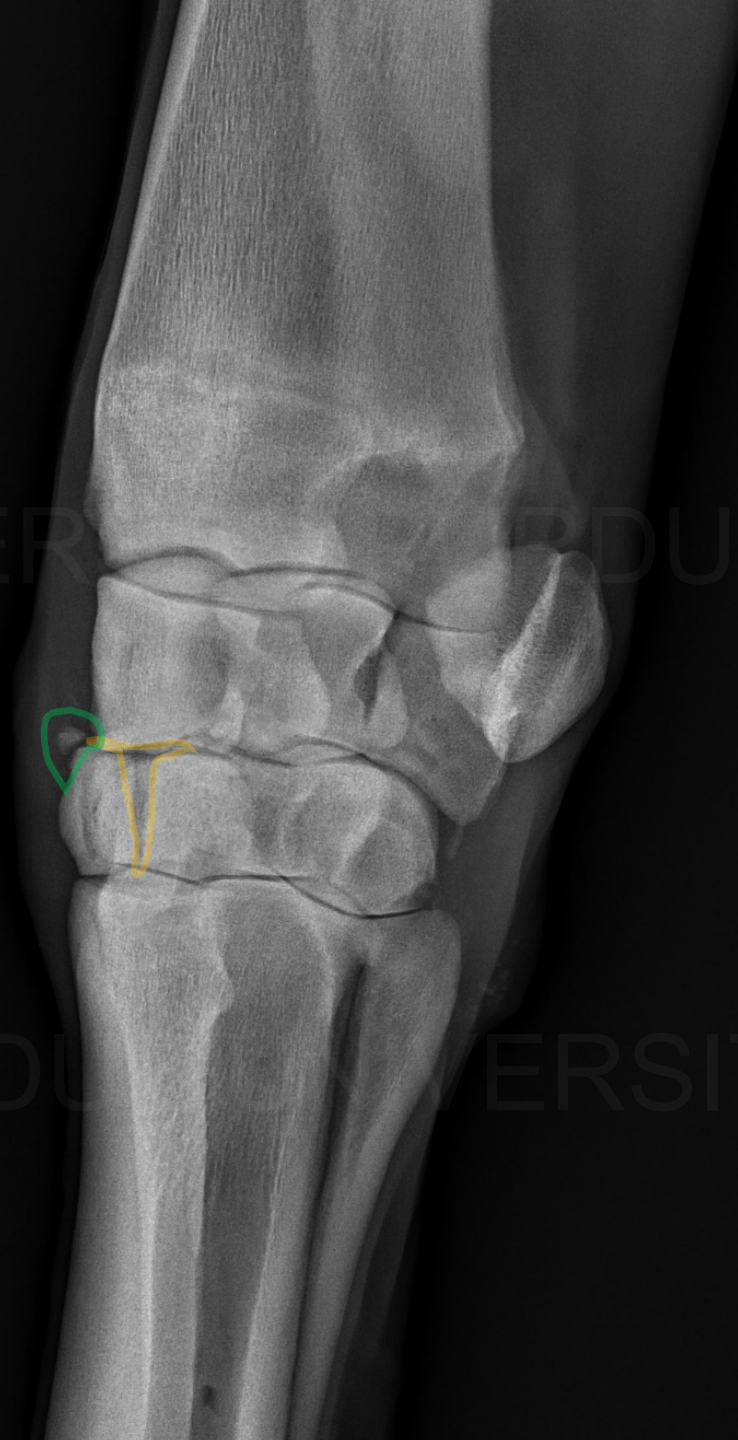
Well defined, wedge-
shaped, decreased
mineral opacity in the 3rd
carpal bone



Small rounded, periarticular, mineral opacity at the dorsomedial aspect of the 3rd carpal bone

0M9J0

REFRONT

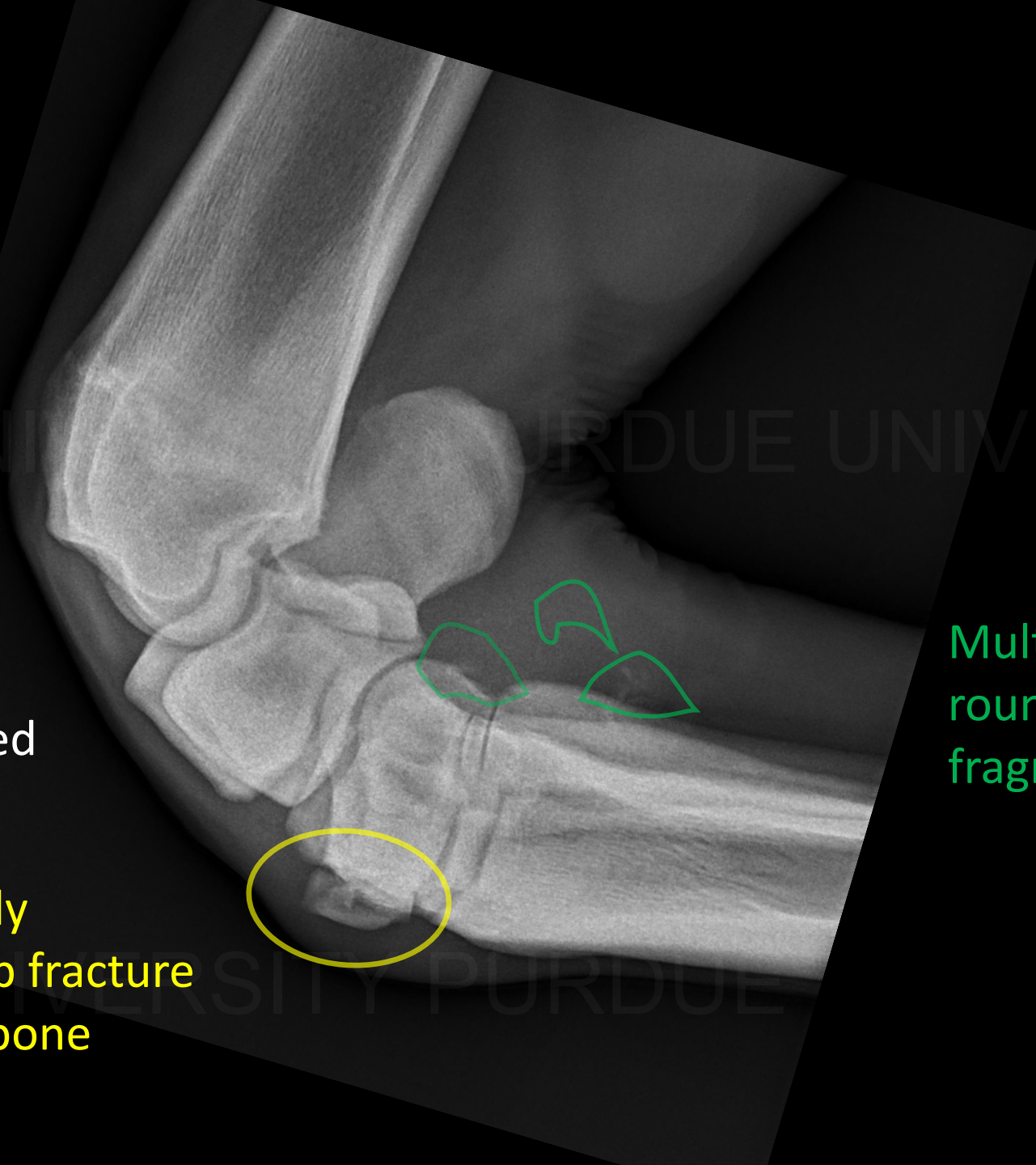


Well defined, wedge-shaped, decreased mineral opacity in the 3rd carpal bone

LM flexed
RFRONT

Mildly dorsally
displaced slab fracture
of 3rd carpal bone

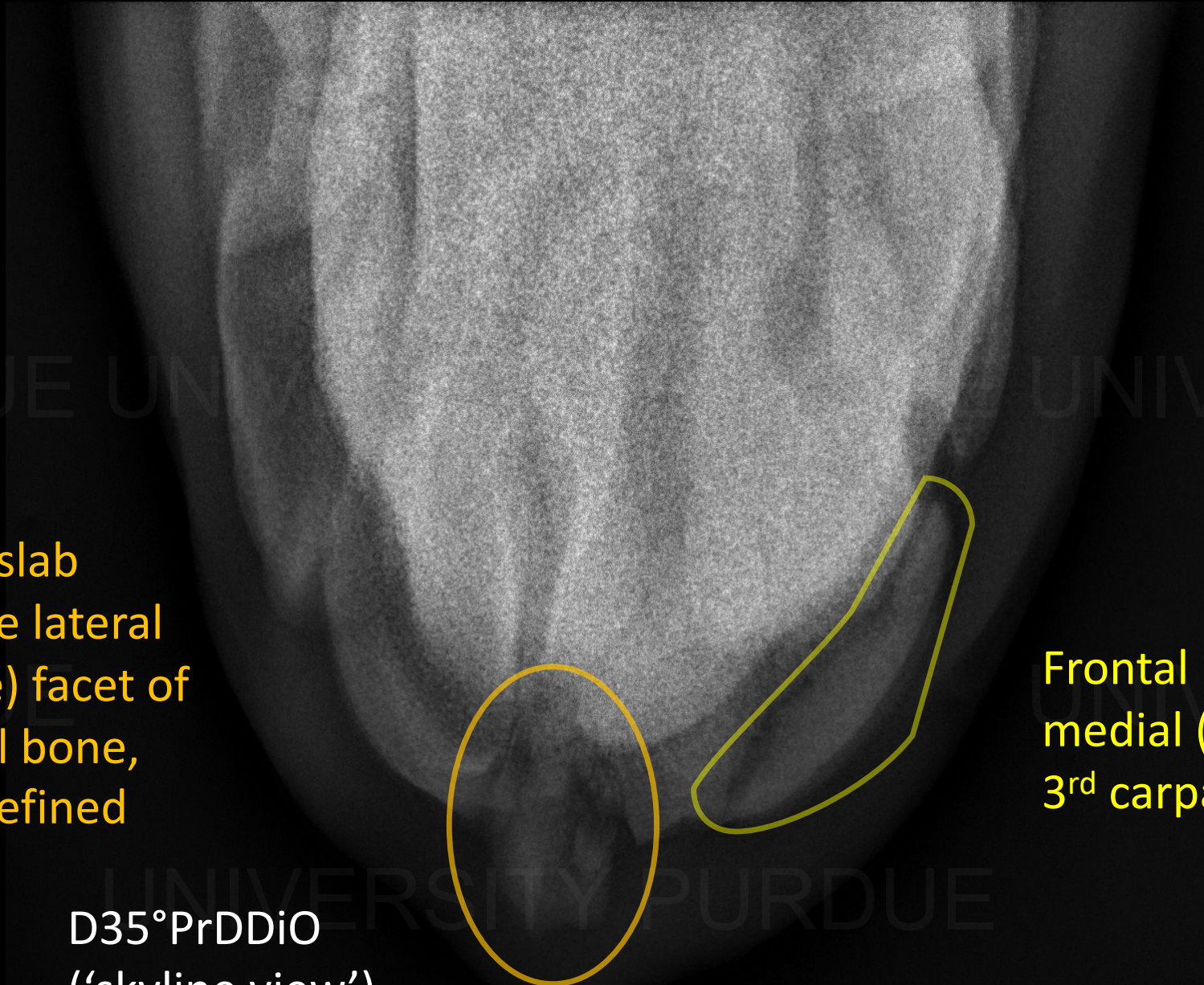
Multiple small
rounded mineral
fragments



Sagittal plane
comminuted slab
fracture of the lateral
(intermediate) facet of
the 3rd carpal bone,
with poorly defined
margins

D35°PrDDiO
('skyline view')
RFRONT

Frontal plane fracture of
medial (radial) facet of
3rd carpal bone



Radiographic Diagnosis

Multifocal subacute displaced articular 3rd carpal bone fractures with hemorrhage and / or synovitis, most likely due to stress-related bone injury

Remarks

- Slab fractures
 - Standardbred and Thoroughbred racehorses commonly affected
 - More common in right carpus of thoroughbreds
 - Evenly distributed in Standardbreds
- Fracture of the 3rd carpal bone
 - Radial facet is more common than intermediate facet
 - Frontal plane is more common than sagittal

Remarks

- Pathogenesis
 - Chronic cyclic loading and compression forces → repetitive stress/trauma leading to microfractures and/or cartilage damage → subchondral bone sclerosis → decreased compliance → fracture

Remarks

- Diagnosis of slab fractures
 - Radiographs – may be seen on lateromedial or flexed lateromedial views
 - Easier to see when displaced
 - But, if suspected, 'Skyline' views are recommended
 - Sagittal fractures can often ONLY be seen on skyline views
 - 3rd carpal bone is usually sclerotic (radial facet > intermediate facet)

Remarks

- Treatment options – depend on location and size
 - Surgical/arthroscopic removal
 - Reduction with surgical implants
 - Conservative management with stall rest

Remarks

- Prognosis/outcome
 - Variable depending on location and type
 - 65% and 77% of Thoroughbreds and Standardbreds, respectively, returned to racing in one study
 - Earning per start however declined
 - 69% of horses in another study raced at least once after treatment
 - Surgical > arthroscopic debridement > conservative management
 - More recent study showed less favorable prognoses dependent on presence of concurrent joint pathology (ie cartilaginous damage)
 - 42% Thoroughbreds and 67% Standardbreds returned to racing

References

- Burguez PN. Interpreting radiographs 4: The carpus. *Equine Vet J*. 1984 May;16(3):159-62.
- Palmer SE. Prevalence of carpal fractures in thoroughbred and standardbred racehorses. *J Am Vet Med Assoc*. 1986 May 15;188(10):1171-3.
- Fischer AT Jr, Stover SM. Sagittal fractures of the third carpal bone in horses: 12 cases (1977-1985). *J Am Vet Med Assoc*. 1987 Jul 1;191(1):106-8.
- Haan, CE. A radiographic investigation of third carpal bone injury in 42 racing Thoroughbreds. *Vet Radiol* 1987;28:88–92.

References

- Stephens, PR. Slab fractures of the third carpal bone in standardbreds and thoroughbreds: 155 cases (1977–1984). *J Am Vet Med Assoc* 1988;193:353–358.
- Schneider RK, Bramlage LR, Gabel AA et al. Incidence, location and classification of 371 third carpal bone fractures in 313 horses. *Equine Vet J Suppl.* 1988 Sep;(6):33-42.
- Kraus BM, Ross MW, Boston RC. Surgical and nonsurgical management of sagittal slab fractures of the third carpal bone in racehorses: 32 cases (1991-2001). *J Am Vet Med Assoc.* 2005 Mar 15;226(6):945-50.
- Doering AK, Reesink HL, Luedke LK et al. Return to racing after surgical management of third carpal bone slab fractures in thoroughbred and standardbred racehorses. *Vet Surg.* 2019 May;48(4):513-523.